

Pectoralis Major Myocutaneous Flap For Reconstruction Of Major Neck Defects Following Surgery For Head And Neck Tumors. A 5-Years Multicenter Experience.

Emad M. Abdelrahman¹, Mohamed O. Elshaer ¹, Ahmed Saaduddin Sapri², Ahmed A. Shoulah ³, Mohamed H. Abdelhalim ³, Samir M. Halawa⁴, Mostafa Gomaa Sobhy⁵, Rami F. Tantawy⁵, and Ahmed M. Abostate¹

¹ General Surgery Department, Faculty of Medicine, Benha University, Egypt.

² Department of Oral Surgery, Faculty of Dentistry, Mansoura University

³ Plastic Surgery Unit, Benha Faculty of Medicine, Benha University

⁴ Fellowship of oral and maxillofacial Surgery, Benha university Hospital, Egypt

⁵ Otolaryngology Department, Faculty of Medicine, Benha University, Egypt.

Original

Article

Abstract

Background: Surgeons have long faced the difficulty of reconstructing head and neck defects following treatments for malignancy. In addition to offering a reconstructive choice of acceptance in terms of color, texture, and advantageous scar position.

Aim of the study was to document the utility and outcomes with the reconstruction of neck defects using Pectoralis Major Myocutaneous Flap (PMMC).

Methodology: The current study included 43 patients who were operated on for neck malignancies where wide composite excision with remaining large defect eligible for reconstruction using PMMC. Follow-up was planned for at least 12 months postoperatively for the post-operative complications and aesthetic outcome.

Results: In the current study the mean age of the included patient was 55.63 ± 4.22 . Among them 44.2 % presented with salivary gland tumors. The mean operative time was 6.25 ± 0.75 hours with a mean of 5.22 ± 0.67 days hospital stay. The postoperative wound infection was reported in 16.3 % of patients, wound dehiscence in 16.3 % of patients with no reported total flap loss. Partial flap loss was reported in 6 patients (13.95 %). There was a strong positive correlation between patient evaluation and independent surgeons' assessment ($r=0.821$).

Conclusion: PMMC flap is a reliable option for the reconstruction of large neck defects. It is easy to be harvested with minimal postoperative complications and accepted aesthetic outcomes.

Keywords: Neck malignancies, PMMC flap, Neck reconstruction

Received: 15 July 2024. Accepted: 10 August 2024

Correspondence to: Emad M. Abdelrahman, MD, General Surgery Department, Faculty of Medicine, Benha University, Egypt. **Tel:** +201226763987. **Email:** emadsahan301@gmail.com and emad.sarhan@fmed.bu.edu.eg

ISSN:1110-1121 Egyptian Journal of Surgery

Introduction

The prognosis for people with head and neck cancer (HNC) has greatly improved in recent years. More long-term survivors have resulted from this [1-3]. The most crucial outcome for HNC patients is survival, but as a result of this trend, other aspects of treatment outcomes, such as physical and psychological status, functional abilities, and well-being, as well as social interactions, are becoming more and more significant [4-5].

Tumors of the head and neck can cause severe deficiencies in appearance and functions, which can have -ve effects on one's physical, mental, and nutritional health. For the past 35 years, the overall survival rate for patients with HNC has not changed, despite recent advancements in medical science. The principles of tumor excision with maximum tissue removal without compromising overall survival have been established as a result of this survival rate. (6)

Surgeons have long faced the difficulty of reconstructing head and neck abnormalities following ablative treatments for a primary or recurrent malignancy. In addition to offering sufficient covering, the reconstructive choice should also offer a good match in terms of color, texture, and advantageous scar position. For the same reason, a variety of options are available, including vascularized free flaps, fasciocutaneous or myocutaneous flaps, and local rotation flaps. Vascularized flaps are great, but they are frequently left out of the toolkit because of poor skin texture match, atherosclerotic alterations in the vasculature, comorbidities, advanced age, incapacity for lengthy operation, or budgetary limitations. Local flaps are therefore the mainstay of rebuilding in environments with limited resources. (7,8)

Reconstruction becomes more difficult when there is a large through-and-through cheek defect combined with a large outer skin defect involving the neck. This is because of the size of the defect, the need for two local flaps, the distance from the donor site, and the closure of the donor site defect. It becomes more difficult when local flap was previously used during initial surgery for recurring head and neck tumors. Reconstruction of a significant defect in the neck after primary neck cancer excision or after removal of skin implicated in lymph node recurrence is especially difficult since cosmesis and sufficient skin cover must be perfectly balanced.(7)

A patient's quality of life (QOL) can be greatly impacted by head and neck deformities, which are among the most incapacitating and socially isolating impairments. They can also have a devastating effect on a patient's look and function. Plastic surgeons still face a very difficult task when reconstructing problems of this kind because their goal is to restore function and shape with the least amount of surgical morbidity possible.(9)

Because of its vascularity and low learning curve for surgeons, the pectoralis major myocutaneous (PMMC) flap

remains a mainstay at facilities with a high patient volume and limited resources.(10) Despite the literature indicating a complication rate of 17–63% and forty years after Ariyan's initial description, it continues to enjoy unparalleled acceptability in head and neck reconstruction.[8–12] The primary method of reconstruction after composite resections is the PMMC flap. It offers the necessary mass to produce a composite defect with aesthetically acceptable results. (11–13)

The outcome of PMMF flap in reconstruction of major neck defects following Surgery for neck tumor is still questionable and this had motivated the authors to conduct this study

Patients and methods

Study design

The current retrospective study was conducted following the ethical perspectives of Helsinki consideration at the Surgery Department, ENT Benha University Hospital and Department of Oral Surgery, Faculty of Dentistry, Mansoura University.

The study included 43 patients who were operated on for neck malignancies (**Figure 1**) where wide composite excision with remaining large defect eligible for reconstruction using PMMF. throughout the period from January 2017 till March 2023. Exclusion criteria included patients with previous irradiation to the chest wall, patients with collagen disease like scleroderma or those who refused to be included within the study

Approval to conduct the research will be obtained from the ethical and research committee, Benha University. A written informed consent will be obtained from all included patients.

Prior to surgery, a complete medical history was obtained, paying particular attention to any prior surgeries that would have compromised the flap's blood supply.

preoperative tumour biopsies in order to confirm the disease histologically was mandatory. Additionally, the

patient needs to be counseled with potential cosmetic abnormalities

Procedure

A broad-spectrum antibiotic is given before surgery.

The first step is the procedure included radical excision of the 1ry tumor together with Bilateral block neck dissection (**Figure 2**) and this excision was planned according to the site of the primary tumor (**Figure 1**) For example radical submandibular sial adenectomy, radical thyroidectomy, or even wide local excision of cutaneous tumors like squamous cell carcinoma with a safety margin

Then the PMMS flap was done

Two lines were drawn to represent the vascular pedicle's surface: one from the ipsilateral acromion to the xiphisternum, and the other vertically from the clavicle's midpoint to the intersection of the first line. Over the pectoralis muscle, along the pectoral branch of the thoracoacromial artery, was where the flap's skin paddle was placed. (**Figure 3**)

To incorporate as many myocutaneous perforators as possible, care was taken to bevel rather than undercut the skin paddle during flap elevation. To reduce the possibility of myocutaneous perforators being sheared, the skin paddle was sutured to the underlying pectoralis muscle using a few stitches.

By dissecting the lateral edge of the pectoralis major muscle, the dissection plane between the pectoralis minor and pectoralis major muscle with its vascular pedicle was discovered. Once in the plane, we had little trouble releasing the pectoralis minor muscle from the pectoralis major, which has a vascular pedicle (**Figure 4**). The muscle known as the pectoralis major was split lateral to the pedicle, maintaining its visibility, and releasing it from the humerus. To make room for the neurovascular pedicle and its adventitia alone, a section of the muscle's clavicular fibers were split, removing

The hump above the collarbone. Now, a subcutaneous tunnel was made just below the collarbone, via which the flap was inserted into the neck (**Figure 5**). The tunnel's width allowed for the flap to be delivered into the neck with ease and without being compressed. The flap was successfully sutured using 3-0 vicryl interrupted sutures or using clips (**Figure 6**). The wounds were bandaged in layers, and suction drains were inserted into the neck and chest. Due to the constant closure of the donor site, significant fasciocutaneous flap mobilization was necessary.[14]

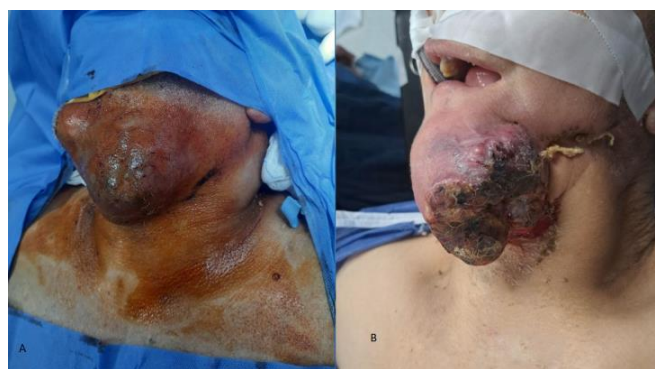

Figure 1 A,B : 1ry tumor of Submandibular and Skin.

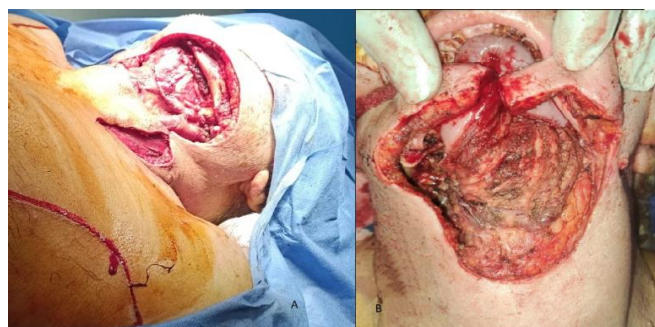

Figure 2 A,B : Radical excision of the tumor

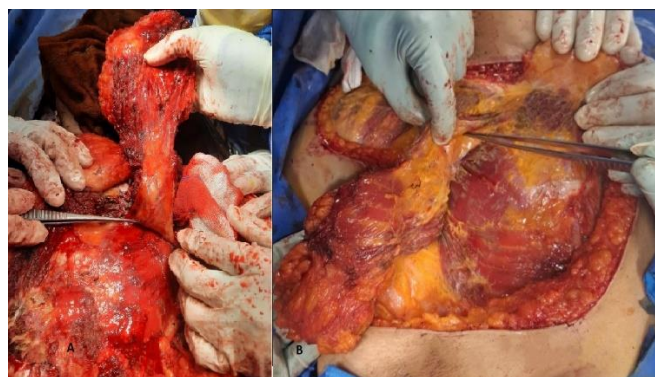

Figure 3 A,B : Marking of the PMMC flap island

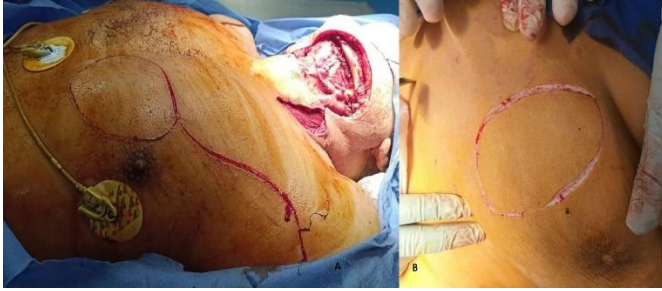

Figure 4 A,B : PMMC flap dissection and mobilization

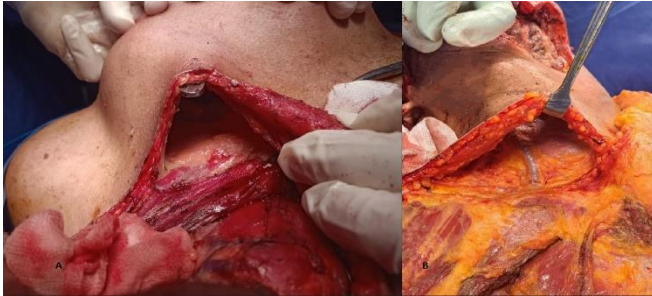

Figure 5 A,B : Creation of SC tunnel for flap transfer to the neck

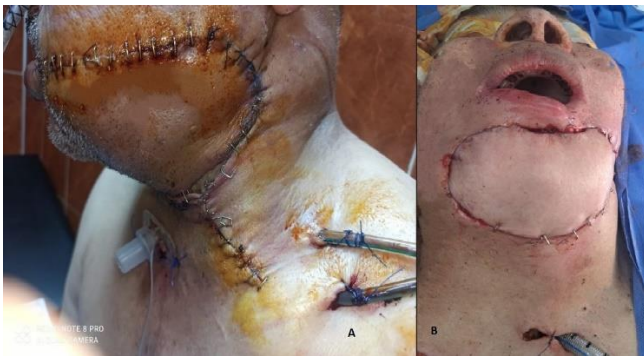


Figure 6 A,B: insetting of the flap

The site of the chest donation is irrigated, and the region is examined to guarantee careful hemostasis. Ideally, the chest is lined with two closed suction drains, which are subsequently closed in two layers based on the surgeon's discretion. Chest wall closure might be facilitated by more undermining. A certain amount of stress in the chest wall closure is normal. Similar to the majority of patients undergoing head and neck reconstruction, precautions are required to prevent tight neck ties and undue strain on the pedicle. In order to prevent the nursing staff from misinterpreting the bulge for a growing hematoma, it may

be advantageous to mark the location on the chest wall where the PMMC flap is rotated on itself.[15]

Follow up and outcomes

The mean operative time, operative stay, intraoperative complications and postoperative complications were reported

Follow-up was planned for at least 12 months postoperatively for the post operative complications and aesthetic outcome

Outcomes:

The 1ry outcome was to surgical removal the neck tumors on basis of oncological safety with successful closure of the defect using PMMC flap with minimal postoperative complications

The 2ry outcome was obtaining good esthetic outcome with accepted patient satisfaction.

The secondary outcome assessed using The Likert scale where the results were simply provided as a five-point scale (1 being great, 2 being good, 3 being fair, 4 being poor, and 5 being bad). On the other hand, evaluation of the final scar appearance produced the desired aesthetic result. Three separate plastic surgeons completed this using Vancouver's scar scale which rates scars in four primary categories: height, vascularity, pliability, and pigmentation (Table 1). The total score goes from 0 (normal skin tone) to 13 (worst possible automobile).[16]

Statistical analysis

The sample size was estimated using the G*power 3.1 tool at Universities, Dusseldorf, Germany. The sample size was determined using post-operative issues, the main endpoint of the current investigation. With a 0.9 effect size, 95% power, and 0.05 type 1 error (2 tailed), 43 patients were enrolled.

For the statistical study, IBM Corp., Armonk, New York, USA, provided SPSS, version 25. For quantitative factors that were reported using mean and SD, the student t-test was employed. For qualitative indicators that were

expressed as the frequency with percent, the χ^2 test was employed. P-values below 0.05 were regarded as significant.

The linear association between Person's VSS and patient satisfaction, two quantitative variables, was measured using the rank correlation coefficient (r).

Table 1: Vancouver Scar scale[13]

Scar characteristic		Score
Vascularity	Normal	0
	Pink	1
	Red	2
	Purple	3
Pigmentation	Normal	0
	Hypopigmentation	1
	Hyperpigmentation	2
Pliability	Normal	0
	Supple	1
	Yielding	2
	Firm	3
	Ropes	4
	Contracture	5
Height (mm)	Flat	0
	< 2	1
	2-5	2
	> 5	3
Total score		13

Results:

In the current study the mean age of the included patient was 55.63 ± 4.22 . Among them 44.2 % presented with salivary gland tumors. Other sociodemographic data and tumor types were reported in table 1. The mean operative time was 6.25 ± 0.75 hours with a mean of 5.22 ± 0.67 days hospital stay Table 1.

Table 1 reported the postoperative wound infection in 16.3 % of patients, wound dehiscence in 16.3 % of patients, hematoma in 4.65 % of cases, seroma in 4.65 % of cases

with no reported total flap loss. Partial flap loss was reported in 6 patients (13.95 %).

Using Likert scale [14], patients' satisfaction was evaluated. Patients were evaluated from excellent to poor, with the highest percentage was good (60.5 %) and least was poor (6.98 %). The esthetic outcome using Vancouver's scar scaler ranged from 1 to 7, with a mean of 4.76 ± 1.22 (Table 3). There was a strong positive correlation between patients' evaluation and independent surgeons' assessment ($r=0.821$).

Table 2: Sociodemographic data, operative data, postoperative complications

variable	N=43	
Sociodemographic data		
Age	Mean \pm SD	55.63 ± 4.22
Sex	N (%)	
Male		24 (55.8 %)
Female		19 (44.2 %)
Comorbidities		
HTN	N (%)	13 (30.2 %)
DM	N (%)	15 (34.9 %)
IHD	N (%)	11 (25.6 %)
Operative data		
Operative time (hours)	Mean \pm SD	6.25 ± 0.75
Hospital Stay (days)	Mean \pm SD	5.22 ± 0.67
Tumor characteristics		
Salivary gland tumors	N (%)	19 (44.2 %)
Skin tumors	N (%)	16 (37.2 %)
Others	N (%)	7 (16.3 %)
Post operative complications		
Wound infection	N (%)	7 (16.3 %)
Wound dehiscence	N (%)	7 (16.3 %)
hematoma	N (%)	2 (4.65 %)
Seroma	N (%)	2 (4.65 %)
Total flap loss	N (%)	0 (0 %)
Partial flap loss	N (%)	6 (13.95 %)

Table 3 Patients' satisfaction and physician's evaluation

variable	N=43
Patients' satisfaction	N (%)
• Excellent	• 4 (9.3%)
• Fair	• 10 (23.26%)
• Good	• 26 (60.5 %)
• Poor	• 3(6.98 %).
Physician evaluation	
• Range	3-9
• Mean±SD	4.76±1.22

Discussion:

Currently, free flap reconstruction is the best option for head and neck reconstruction since it offers a one-stage reconstruction with better cosmetic and functional outcomes and less morbidity[17]. Nonetheless, PMMC flap is still a valuable tool in the toolbox of head and neck surgeons, particularly in especially in centers with h limited resources. Younger surgeons pick up the operation quickly with the short learning curve. Furthermore, a single team could finish the procedure, avoiding the logistical challenge of having two teams collaborate constantly.[15] In 1979, Arihan first presented the PMMF for head and neck reconstruction [18]. The most significant benefits of PMMF are its relative simplicity in terms of harvesting, its close proximity to the head and neck, and the way the muscle pedicle covers and protects the critical structures of the neck. Even with the advent of free tissue transfer, PMMF is still useful in situations where facilities lacking support for microvascular surgery, or as a salvage procedure in the event that free flaps fail.[19]

Although PMMF has been used extensively in head and neck reconstruction, there have been some reported side effects, including a high rate of whole or partial flap necrosis due to restricted cephalad extension. There have been several attempts to enhance the restricted cephalad extension. It is important to note that extending the flap

transfer via the subclavicular route results in a reduction in the frequency of flap loss [20, 21]. Although some researchers stated that the subclavicular approach would raise the potential morbidity, a modified skin paddle design with a subclavicular tunnel could enhance the length of the vascular pedicle.[22]

In the current study, 14 (32.6%) cases reported post-operative complications and this matched the reports of the available literature on PMMC flap reconstruction where reported complications vary from 17% to 63%.[12,13,23] . Survival is a key benefit of PMMC flaps. Total flap necrosis can occur in free flap reconstructions, even in the hands of a skilled microsurgeon; total loss of PMMC flaps is uncommon[24]. Many authors [11–13,23–25] did not record any whole flap loss, which was consistent with the current findings that no cases of total flap loss were reported.

The occurrence of flap necrosis has been linked to numerous technical criteria, including the energy source type employed during dissection, whether the pectoralis muscle's clavicular attachment is preserved or removed, and the existence of an arbitrary part of skin at the flap's distal end.[11,12, 18]

The skin island covering the upper part of the pectoris major muscle receives its primary blood supply from the pectoral branch of the TAA, whereas the skin region covering the lower part of the PMMF is supplied by the anterior intercostal branches of the internal mammary artery (IMA) and the LTA. Since there is a high risk of distal flap necrosis when only the main trunk is preserved in a conventional harvesting procedure for head and neck reconstruction, the LTA and IMA are cut to prevent compromise of the flap rotation arc. This is especially true when the skin island is designed in the lower chest to gain sufficient pedicle length. [21]

Partial flap loss was reported in the current study in 6 patients (14%) and all cases were treated by debridement

and 2 ry sutures or the wound was left open till healing and this was too much less than what was reported by many studies and this is assumed to be due to several factors the first one is the inclusion of neck tumors only in the current study with no need for over stretch of the flap to reach defects in head tumors at a higher level. The strict adherence to the anatomical considerations outlined by Lyu X et al. [21] during flap harvesting. The preservation of the LTA and the pectoral branch of the TAA was the second factor contributing to the study's lower reported cases of flap loss. This was accomplished by placing the skin paddle in the correct location. The skin paddle was designed with the lateral margin 2 to 3 cm from the edge of the pectoralis major muscle, the lower margin up to the level of the seventh costal cartilage, the medial margin around the outer edge of the sternum, and the upper margin at the level of the fourth costal cartilage. These results aligned with the study by Rikimaru et al. [26] who Place the skin island just medially to the nipple, across the fourth, fifth, and sixth intercostal spaces, to cover the skin perforator vessels that originate from the internal thoracic artery's intercostal branches [26, 27].

Higher incidences of complete flap necrosis (2%–4%) and partial skin paddle necrosis (11.1%–24.5%) were found in most large cohort studies. [13, 27] Anatomical studies have confirmed the significant contribution of the LTA to PMMF, and clinical trials have shown that a bigger vascular pedicle may improve blood flow.[28–30]

Infection is a serious problem with PMMC flap reconstruction, just like it is with other major surgeries. The best defense against it is to follow asepsis strictly. Other complications that were reported in the current study included hematoma that developed in 2 patients, seroma in 2 patients, wound dehiscence in 7 patients and this was in line with the reports of many authors [15] although there was less wound infection (14%) in the current study when

compared to the results of Tripathi M et al who reported 32 % wound infection.

Rauchenwald T et al [31] reported favorable quality of life following PMMS with composite scores, social-emotional sub-scores, and average physical function aligning with acceptable standard of aesthetic outcome and this matched the results of the current study where more than 83% of cases reported satisfactory aesthetic outcome with significant correlation between patient assessment and independent investigatou assessment

Conclusion

PMMC flap is a reliable option for the reconstruction of large neck defects. It is easy to be harvested with with minimal postoperative complications and accepted aesthetic outcome.

Declaration of conflicting interests: NIL.

Funding: NIL

References

1. Chow L. Head and Neck Cancer. *N Engl J Med*. 2020; 2;382(1):60-72. doi: 10.1056/NEJMra1715715.
2. León X, Orús C, Casasayas M, Neumann E, Holgado A, Quer M. Trends in disease-specific survival of head and neck squamous cell carcinoma patients treated in a single institution over a 30-year period. *Oral Oncol*. 2021;115:105184. doi: 10.1016/j.oraloncology.2021.105184.
3. Johnson D, Burtneß B, Leemans C, Lui V, Bauman J, Grandis J. Head and neck squamous cell carcinoma. *Nat Rev Dis Primers*. 2020; 26;6(1):92. doi: 10.1038/s41572-020-00224-3..
4. Ringash J, Bernstein L, Devins G, Dunphy C, Giuliani M, Martino R et al. Head and Neck Cancer Survivorship: Learning the Needs, Meeting the Needs. *Semin Radiat Oncol*. 2018 ;28(1):64-74. doi: 10.1016/j.semradonc.2017.08.008.
5. Riechelmann H, Dejaco D, Steinbichler T, Lettenbichler A, Anegg M, Ganswindt U et al.

- Functional Outcomes in Head and Neck Cancer Patients. *Cancers (Basel)*. 2022 ; 25;14(9):2135. doi: 10.3390/cancers14092135.
6. Bornbaum CC, Fung K, Franklin JH, Nichols A, Yoo J, Doyle PC. A descriptive analysis of the relationship between quality of life and distress in individuals with head and neck cancer. *Support Care Cancer*. 2012 Sep;20(9):2157-65. doi: 10.1007/s00520-011-1326-2. Epub 2011 Nov 30. PMID: 22124527.
7. Kumar NAN, Dikhit PS, Usman N, Rajan K, Shetty PS. The contralateral based Cervico-pectoral rotation flap for large neck defects. *Oral Maxillofac Surg*. 2022 Dec;26(4):581-586. doi: 10.1007/s10006-021-01022-1. Epub 2021 Nov 21. PMID: 34802098; PMCID: PMC9643203.
8. Liu F, Xu Z, Li P, Sun C, Li R, Ge S et al. The versatile application of cervicofacial and cervicothoracic rotation flaps in head and neck surgery. *World J Surg Oncol*. 2011; 23;9:135. doi: 10.1186/1477-7819-9-135.
9. Maurer J, Hipp M, Schäfer C, Kölbl O. Dysphagia. Impact on quality of life after radio(chemo)therapy of head and neck cancer. *Strahlenther Onkol*. 2011;187(11):744-9. doi: 10.1007/s00066-011-2275-x.
10. McCrory A, Magnuson J. Free tissue transfer versus pedicled flap in head and neck reconstruction. *Laryngoscope*. 2002;112(12):2161-5. doi: 10.1097/00005537-200212000-00006.
11. Milenović A, Virag M, Uglesić V, Aljinović-Ratković N. The pectoralis major flap in head and neck reconstruction: first 500 patients. *J Craniomaxillofac Surg*. 2006;34(6):340-3. doi: 10.1016/j.jcms.2006.04.001.
12. Croce A, Moretti A, D'Agostino L, Neri G. Continuing validity of pectoralis major muscle flap 25 years after its first application. *Acta Otorhinolaryngol Ital*. 2003;23(4):297-304.
13. Liu R, Gullane P, Brown D, Irish J. Pectoralis major myocutaneous pedicled flap in head and neck reconstruction: retrospective review of indications and results in 244 consecutive cases at the Toronto General Hospital. *J Otolaryngol*. 2001;30(1):34-40. doi: 10.2310/7070.2001.21011.
14. Watts T: The pectoralis major myocutaneous flap. *Operative Techniques in Otolaryngology* .30 (2019) 134–137
15. Tripathi M, Parshad S, Karwasra R, Singh V. Pectoralis major myocutaneous flap in head and neck reconstruction: An experience in 100 consecutive cases. *Natl J Maxillofac Surg*. 2015;6(1):37-41. doi: 10.4103/0975-5950.168225.
16. Abdelrahman E, Shoulah A, Ghaza S, Nchoukat M, Balbaa A. Cheek advancement flap for nasal reconstruction following surgical excision of basal cell carcinoma: early outcome and patient satisfaction. *The Egyptian Journal of Surgery*. 2021. 40(1):p 322-329, | DOI: 10.4103/ejs.ejs_347_20
17. Vartanian J , Carvalho A, Carvalho S, Mizobe L, Magrin J, Kowalski P. Pectoralis major and other myofascial/myocutaneous flaps in head and neck cancer reconstruction: experience with 437 cases at a single institution. *Head Neck*. 2004;26(12):1018-23. doi: 10.1002/hed.20101.
18. Ariyan S. The pectoralis major myocutaneous flap. A versatile flap for reconstruction in the head and neck. *Plast Reconstr Surg*. 1979;63(1):73-81. doi: 10.1097/00006534-197901000-00012.
19. Castelli M, Pecorari G, Succo G, Bena A, Andreis M, Sartoris A. Pectoralis major myocutaneous flap: analysis of complications in difficult patients. *Eur Arch Otorhinolaryngol*. 2001;258(10):542-5. doi: 10.1007/s004050100389.

20. Poh E, Xu L, Yin X, Shen S. Extending the Arc of Rotation of the Pectoralis Major Myocutaneous Flap for Orofacial Reconstruction via a Modified Subclavicular Route Through the Clavipectoral Fascia. *J Oral Maxillofac Surg.* 2017;75(1):222.e1-222.e6. doi: 10.1016/j.joms.2016.09.001. Epub 2016 Sep 14. Erratum in: *J Oral Maxillofac Surg.* 2017 Feb;75(2):441.
21. Lyu X, Liu S, Zheng L, Huang M, Zhang J, Zhang J. A Modified Design of the Pectoralis Major Myocutaneous Flap for Reconstruction of Head and Neck Defect. *J Craniofac Surg.* 2021; 01;32(5):1762-1764. doi: 10.1097/SCS.00000000000007287.
22. Vanni C, Pinto F, de Matos L, de Matos M, Kanda J. The subclavicular versus the supraclavicular route for pectoralis major myocutaneous flap: a cadaveric anatomic study. *Eur Arch Otorhinolaryngol.* 2010;267(7):1141-6. doi: 10.1007/s00405-010-1203-5.
23. Shah J, Haribhakti V, Loree T, Sutaria P. Complications of the pectoralis major myocutaneous flap in head and neck reconstruction. *Am J Surg.* 1990;160(4):352-5. doi: 10.1016/s0002-9610(05)80541-0.
24. McLean J, Carlson G, Losken A. The pectoralis major myocutaneous flap revisited: a reliable technique for head and neck reconstruction. *Ann Plast Surg.* 2010;64(5):570-3. doi: 10.1097/SAP.0b013e3181c51f4a.
25. El-Marakby H. The reliability of pectoralis major myocutaneous flap in head and neck reconstruction. *J Egypt Natl Canc Inst.* 2006;18(1):41-50.
26. Rikimaru H, Kiyokawa K, Inoue Y, Tai Y. Three-dimensional anatomical vascular distribution in the pectoralis major myocutaneous flap. *Plast Reconstr Surg.* 2005;15;115(5):1342-52; discussion 1353-4. doi: 10.1097/01.prs.0000156972.66044.5c.
27. Avery C, Gandhi N, Peel D, Neal C. Indications and outcomes for 100 patients managed with a pectoralis major flap within a UK maxillofacial unit. *Int J Oral Maxillofac Surg.* 2014;43(5):546-54. doi: 10.1016/j.ijom.2013.10.009.
28. Yang D, Marshall G, Morris S. Variability in the vascularity of the pectoralis major muscle. *J Otolaryngol.* 2003;32(1):12-5. doi: 10.2310/7070.2003.35357.
29. Po-Wing Yuen A. Preservation of lateral thoracic artery to improve vascular supply of distal skin without compromising pedicle length in harvesting pectoralis major myocutaneous flap. *J Plast Reconstr Aesthet Surg.* 2006;59(12):1433-5. doi: 10.1016/j.bjps.2006.02.007.
30. Makiguchi T, Yokoo S, Miyazaki H, Takayama Y, Ogawa M, Hashikawa K et al. Supercharged pectoralis major musculocutaneous flap. *J Craniofac Surg.* 2013;24(2):e179-82. doi: 10.1097/SCS.0b013e3182801898.
31. Rauchenwald T, DeJaco D, Morandi E, Djedovic G, Wolfram D, Riechelmann H et al. The Pectoralis Major Island Flap: Short Scar Modified Muscle-Sparing Harvesting Technique Improves Aesthetic Outcome in Reconstructive Head and Neck Surgery. *ORL J Otorhinolaryngol Relat Spec.* 2019;81(5-6):327-337. doi: 10.1159/000503008.